

The American Journal of Sports Medicine

<http://ajs.sagepub.com/>

Arthroscopic Capsular Plication and Labral Preservation in Borderline Hip Dysplasia: Two-Year Clinical Outcomes of a Surgical Approach to a Challenging Problem

Benjamin G. Domb, Christine E. Stake, Dror Lindner, Youssef El-Bitar and Timothy J. Jackson

Am J Sports Med 2013 41: 2591 originally published online August 16, 2013

DOI: 10.1177/0363546513499154

The online version of this article can be found at:

<http://ajs.sagepub.com/content/41/11/2591>

Published by:



<http://www.sagepublications.com>

On behalf of:



American Orthopaedic Society for Sports Medicine

Additional services and information for *The American Journal of Sports Medicine* can be found at:

Email Alerts: <http://ajs.sagepub.com/cgi/alerts>

Subscriptions: <http://ajs.sagepub.com/subscriptions>

Reprints: <http://www.sagepub.com/journalsReprints.nav>

Permissions: <http://www.sagepub.com/journalsPermissions.nav>

>> [Version of Record](#) - Nov 1, 2013

[OnlineFirst Version of Record](#) - Aug 16, 2013

[What is This?](#)



Arthroscopic Capsular Plication and Labral Preservation in Borderline Hip Dysplasia

Two-Year Clinical Outcomes of a Surgical Approach to a Challenging Problem

Benjamin G. Domb,^{*†‡§} MD, Christine E. Stake,[†] MA, Dror Lindner,[†] MD, Youssef El-Bitar,[†] MD, and Timothy J. Jackson,^{†||} MD
Investigation performed at the American Hip Institute, Westmont, Illinois, and Hinsdale Orthopaedics, Hinsdale, Illinois

Background: The role of hip arthroscopy in the treatment of patients with dysplasia is unclear because of the spectrum of dysplasia that exists. Patients with borderline dysplasia are generally not candidates for periacetabular osteotomy because of the invasive nature of the procedure. However, arthroscopy in dysplasia has had mixed results and has the potential to exacerbate instability.

Hypothesis: Patients with borderline dysplasia will demonstrate postoperative improvement, high satisfaction rates, and low reoperation rates after a surgical approach that includes arthroscopic labral repair augmented by capsular plication with inferior shift.

Study Design: Case series; Level of evidence, 4.

Methods: Between April 2008 and November 2010, patients less than 40 years old who underwent hip arthroscopy for symptomatic intra-articular hip disorders, with a lateral center-edge (CE) angle $\geq 18^\circ$ and $\leq 25^\circ$, were included in this study. Patients with Tönnis grade 2 or greater, severe hip dysplasia (CE $\leq 17^\circ$), and Legg-Calve-Perthes disease were excluded. Patient-reported outcome scores, including the modified Harris Hip Score (mHHS), Non-Arthritic Hip Score (NAHS), Hip Outcome Score–Sport-Specific Subscale (HOS-SSS), Hip Outcome Score–Activity of Daily Living (HOS-ADL), and visual analog scale (VAS) for pain were obtained in all patients preoperatively and at 1, 2, and 3 years postoperatively. Revision surgery and complications were recorded for each group.

Results: A total of 26 patients met the criteria to be included in the study. Of these, 22 (85%) patients were available for follow-up. The mean (\pm standard deviation) length of follow-up for this cohort was 27.5 ± 5.5 months (range, 17–39 months) and the average age was 20 years (range, 14–39 years). The mean lateral CE angle was 22.2° (range, 18° – 25°) and the mean Tönnis angle was 5.8° (range, 0° – 17°). There was significant improvement in all patient-reported outcome scores (mHHS, NAHS, HOS-SSS, and HOS-ADL) ($P < .0001$). There was a significant improvement in VAS scores from 5.8 to 2.9 ($P < .0001$). Overall patient satisfaction was 8.4 out of 10. Seventeen patients had good/excellent results (77%). Two patients required revision arthroscopy.

Conclusion: Patients with borderline dysplasia have often fallen into a gray area between arthroscopy and periacetabular osteotomy, and viable treatment options have remained scarce. The current study demonstrates favorable results at 2-year follow-up for an arthroscopic approach that includes labral repair augmented by capsular plication with inferior shift.

Keywords: hip; arthroscopy; dysplasia; capsular plication

The role for hip arthroscopy in the treatment of femoroacetabular impingement has been well delineated.^{4,15,22,26} However, its role in the treatment of patients with

dysplasia remains controversial. Hip dysplasia has been shown to be a cause for early osteoarthritis²⁰ because less stability is provided by the bony articulation and more stress is applied to the cartilage and labrum.²³

Hip preservation surgery in dysplastic patients is often limited to periacetabular osteotomy (PAO), as it has been shown that patients with severe dysplasia, defined as a lateral center-edge (CE) angle less than 15° , can achieve good

clinical results when treated with PAO.^{18,29} Hip arthroscopy in these patients is performed with concomitant PAO.¹⁴ Previous studies on hip arthroscopy in borderline dysplasia have shown conflicting results, with some authors demonstrating good outcomes, emphasizing that the nature of the pathologic changes dictates outcomes.⁵ Some authors have shown higher reoperation rates in patients with borderline dysplasia, especially with labral debridement,¹³ whereas other authors have altogether abandoned hip arthroscopy in the setting of dysplasia.²⁵

Patients with borderline dysplasia, defined as a CE angle of Wiberg³² of 20° to 25°, are a subgroup of patients with hip instability, that is, instability from acetabular undercoverage in the setting of mild dysplasia, and their treatment remains controversial. Open hip preservation specialists are hesitant to perform a PAO given the invasive nature of the procedure, and arthroscopists are hesitant to perform arthroscopy because of the potential to exacerbate the mild dysplasia, leading to potentially devastating outcomes.¹⁹

For patients with borderline dysplasia and instability, the surgical approach used at our institution involves preservation of labral tissue with labral repair or selective debridement in certain cases, minimal to no acetabuloplasty for preservation of articular surface, and capsular plication with an inferior capsular shift. We believe that this approach can be a successful option for patients with mild dysplasia that do not necessitate PAO. The purpose of this article is to prospectively evaluate clinical outcomes in a cohort of patients with borderline dysplasia who were treated with arthroscopic labral preservation and capsular plication and to demonstrate that this is a safe, effective procedure. We hypothesize that patients with borderline dysplasia will demonstrate postoperative improvement, high satisfaction rates, with low complication and reoperation rates.

MATERIALS AND METHODS

At our institution, data are prospectively collected on all patients undergoing hip preservation surgery with institutional review board approval. Patient-reported outcome scores include the modified Harris Hip Score (mHHS),⁴ the Non-Arthritic Hip Score (NAHS),⁸ the Hip Outcome Score—Activities of Daily Living (HOS-ADL), and the Hip Outcome Score—Sport-Specific Subscale (HOS-SSS),¹⁷ which are obtained preoperatively and at 1-year, 2-year, and 3-year follow-up time points; this paper reports on the most recent follow-up. All 4 questionnaires are used,

as it has been reported that there is no conclusive evidence for the use of a single patient-reported outcome (PRO) questionnaire for patients undergoing hip arthroscopy.³⁰ Patient-related outcome scores were obtained at follow-up clinical visits or via e-mail for select patients who could not make follow-up appointments. Patients were considered to have a good/excellent outcome if their mHHS score was greater than 80 points.⁴ Patient satisfaction was rated on a scale of 1 to 10 with 1 being completely unsatisfied and 10 being completely satisfied. Any complications and revision surgeries were noted.

During the study period from April 2008 to November 2010, patients who underwent hip arthroscopy for symptomatic intra-articular hip disorders refractory to nonoperative management, who were less than 40 years old, and who had a lateral angle $\geq 18^\circ$ and $\leq 25^\circ$ were included in the study group. Patients with Tönnis grade ≥ 2 , severe hip dysplasia (CE $\leq 17^\circ$), and Legg-Calve-Perthes disease were excluded. We limited the study group to patients younger than 40 years because we believe that older patients with borderline dysplasia are less optimal candidates for arthroscopy.

Clinical Evaluation

All patients were evaluated by the senior author (B.G.D.), who gave special attention to a history of the hip giving way or pain brought on by motions that externally rotate the affected hip, such as swinging a golf club, pivoting, and changing direction in cutting sports. Physical examination of the hip included routine range of motion (ROM) and strength testing in addition to provocative examination maneuvers to detect instability. The anterior impingement test²⁴ was used to detect the presence of a labral tear. The dial test was used to detect anterior capsular laxity. This is performed with the patient supine and the hip in neutral extension. The leg is internally rotated and then released and allowed to externally rotate. External rotation of the affected hip greater than the contralateral limb is a positive test. It is the senior author's preferred method to detect anterior apprehension with a prone, external rotation test. This test is performed with the patient prone and the affected hip maximally externally rotated with posterior pressure applied to the greater trochanter to translate the femoral head anteriorly. A positive test recreates pain in this position. Radiographs included standing and supine anteroposterior pelvis, false profile, modified Dunn, and cross-table lateral views. All radiographs were assessed by the senior author. The lateral CE angle and acetabular inclination were measured

*Address correspondence to Benjamin G. Domb, MD, American Hip Institute, 1010 Executive Court, Suite 250, Westmont, IL 60559 (e-mail: DrDomb@americanhipinstitute.org).

†American Hip Institute, Westmont, Illinois.

‡Hinsdale Orthopaedics, Hinsdale, Illinois.

§Stritch School of Medicine, Loyola University, Maywood, Illinois.

||Congress Medical Associates, Pasadena, California.

One or more of the authors has declared the following potential conflict of interest or source of funding: This study was funded by the American Hip Institute, which receives funding from Arthrex Inc, MAKO Surgical Corp, Pacira, ATI, and Breg. B.G.D. receives research support and provides consulting services for Arthrex Inc, MAKO Surgical Corp, Pacira, DJO Global, ATI, Orthomerica, and Breg; no direct support was received to sponsor this study. B.G.D. is a member of the AANA Learning Center Committee, holds stocks in Styker and MAKO, and has patent applications pending related to arthroscopic labral reconstruction technique and kit and hip brace. C.E.S. receives research support from MAKO Surgical Corp and salary support from the American Hip Institute.

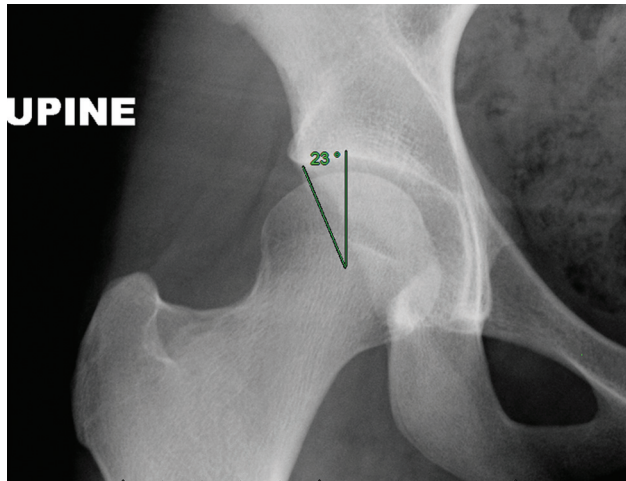


Figure 1. Anteroposterior radiograph of the right hip of a patient with bilateral hip borderline dysplasia. This patient underwent successful bilateral hip arthroscopies, labral repair, and capsular plication. The lateral center-edge angle measures 23°, qualifying this patient as having borderline dysplasia.

(Figure 1). Radiographs were also scrutinized for Tönnis arthritic stage, and patients with stage 2 or greater were excluded.³¹ Cam-type deformity was defined as an alpha angle greater than 50° on the modified Dunn view. All patients in this study underwent a magnetic resonance arthrogram (MRA) preoperatively for assessment of labral and chondral damage. All patients with CE angle less than 20° were referred to an open hip preservation specialist for the consideration of a PAO.

Surgical Technique

Hip arthroscopy was performed with the patient in the modified supine position on a traction table with a well-padded perineal post. Access to the joint was gained as previously described,⁹ through a standard anterolateral portal, an anterior portal placed under direct visualization, and a distal lateral accessory portal for labral repair. The capsule was cut with a beaver blade parallel to the labrum, connecting the anterior and anterolateral portals and extending medially as needed to address all intra-articular lesions. A T-cut was not performed in these patients. Routine diagnostic arthroscopy was performed to assess the ligamentum teres (LT), cartilage surfaces, and labrum. Concomitant procedures were performed if indicated: LT debridement with a radiofrequency device in the case of LT tear; chondroplasty with a motorized shaver for unstable, loose cartilage lesions; and iliopsoas release if the patient had pain with internal snapping of the hip noted on preoperative examination or if there was an iliopsoas impingement lesion on the labrum.¹¹ The clinical indication that is used to perform fractional lengthening of the iliopsoas in these patients is painful internal snapping. We are aware of the theory regarding the dynamic stabilizing effect of the iliopsoas,

and we know that release in the setting of instability is controversial. We believe it is safe to lengthen the iliopsoas in the setting of instability if the static stabilizing capsule is restored. The capsule was elevated from the labrum by use of electrocautery with care taken to preserve capsular tissue for later repair. The acetabular rim was lightly decoricated with use of a round bur to create a surface for the labrum to heal. In cases of coexisting pincer lesions, very minimal rim resection was performed, with care taken not to remove bone from the superolateral aspects of the rim. To preserve as much labral tissue as possible, the labrum was not detached from the chondral junction. Labral repair was performed with 2.9-mm push lock suture anchors (Arthrex, Naples, Florida), with a labral base refixation technique or circumferential suture technique based on labral thickness and quality of tissue.¹² Any torn fibers of the ligamentum teres were debrided with a shaver and electrocautery, leaving healthy, intact fibers. Traction was then released and the hip flexed approximately 45° to evaluate the peripheral compartment. A femoroplasty was performed if a cam deformity was present. The capsule was then closed with a suture shuttle technique as previously described by Domb et al¹⁰; large No. 1 or No. 2 bioabsorbable sutures were used. The femoral side of the capsule was penetrated with a sharp bird-beak grasper inferomedial to the acetabular side of the stitch, through the zona orbicularis (Figure 2). This created an oblique orientation of the suture across the capsule edges. Larger bites yield increased imbrication of the capsule, with the goal to create a 1- to 2-cm shift. This was repeated to allow 4 to 6 sutures to be placed (Figure 3, A and B). The inferomedial location of suture placement on the femoral side advanced the capsule, creating a combined imbrication and inferior capsular shift of the iliofemoral ligament (see the online Video Supplement). After completion of the capsule closure, the arthroscope was left in the peripheral compartment and the leg was then brought into neutral extension to ensure there was no separation of the capsule (Figure 3C). This inferior capsular shift was intended to increase the capsular screw home mechanism in extension and external rotation. Patients were placed in an X-act ROM brace (DJO Global, Vista, California) for 2 weeks and used crutches with touch toe weightbearing for 2 weeks. Physical therapy was begun as early as postoperative day 1 to begin passive ROM with either continuous passive motion or stationary bicycle. Range of motion was restricted for 6 weeks, including limitation of extension to 0° and external rotation to 30° at 90° of flexion and 20° at neutral (prone).

Statistical Analysis

A 2-tailed paired *t* test was used to analyze change in preoperative to postoperative PRO scores (mHHS, NAHS, HOS-ADL, HOS-SSS) and preoperative to postoperative pain (visual analog scale [VAS]). Following previous studies,^{3,22} we performed a power analysis using a mean improvement in mHHS of 20 and a standard deviation of 15. With a power set at 0.8, 22 patients would be needed to have adequate power. A *P* value of <.05 was considered statistically significant.

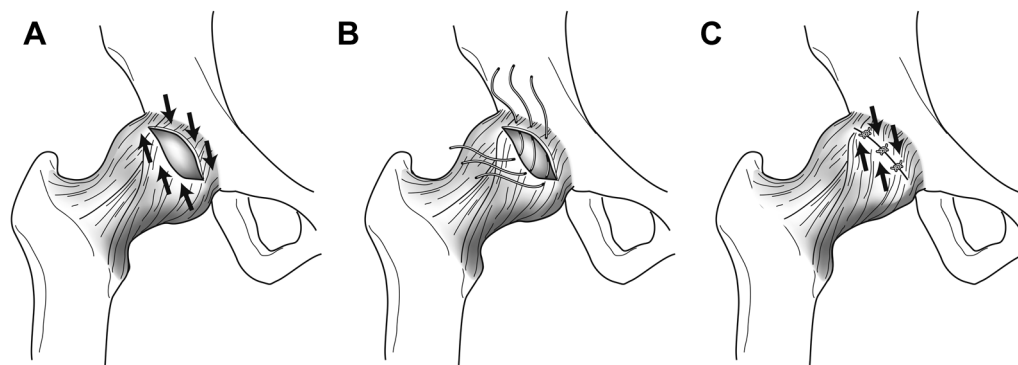


Figure 2. (A) The goal of the closure is to shift the inferior capsule proximally. (B) This is achieved by placing the sutures inferomedially on the inferior side of the capsulotomy. The sutures cross the capsulotomy in an oblique fashion. (C) When the sutures are tied, an inferior capsular shift is produced. (From Domb BG, Philippon MJ, Giordano BD. Arthroscopic capsulotomy, capsular repair, and capsular plication of the hip: relation to atraumatic instability. *Arthroscopy*. 2013;29(1):162-173. © Benjamin G. Domb, MD. Reproduced with permission.)

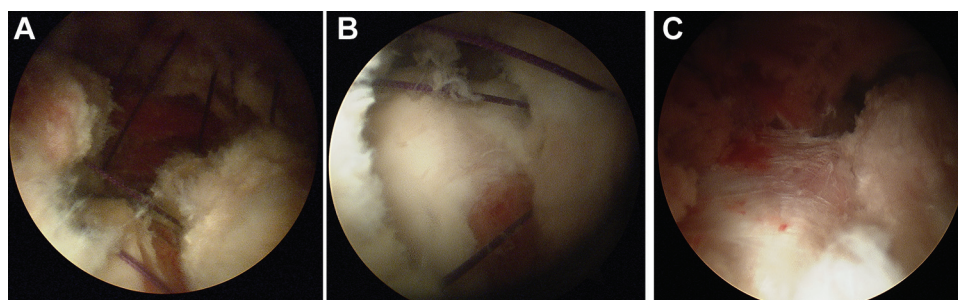


Figure 3. Intraoperative photos of the right hip. (A) Multiple sutures have been passed through the capsule in an oblique orientation. (B) Closer view of the sutures crossing the ends of the capsule. (C) After the sutures have been tied, the capsule is imbricated; with the hip in neutral extension, there is no gapping in the capsule closure.

RESULTS

During the study period, 26 patients met the criteria to be included in the study. Of these, 22 patients (85%) were available for follow-up. One patient had a prior hip arthroscopy at an outside institution. Twenty-one patients underwent primary hip arthroscopy. The mean (\pm standard deviation) length of follow-up for this cohort was 27.5 ± 5.5 months (range, 17-39 months). Patient demographics are shown in Table 1. The mean CE angle was 22.2° (range, 18° - 25°) and Tönnis angle was 5.8° (range, 0° - 17°).

Findings at the time of surgery are detailed in Table 2. All patients had a labral tear, 19 had cartilage damage at the chondrolabral junction, and 13 had ligamentum teres tears. Twenty-one patients underwent labral repair, and 1 patient had minimal labral damage that was amenable to selective debridement with labral preservation. All patients underwent capsular plication as part of the protocol in treating this cohort. Other procedures included femoral osteoplasty in 9 patients, chondroplasty in 9 patients, and ligamentum teres debridement in 13 patients (Table 3).

At final follow-up, there was significant improvement in all patient-reported outcome scores (mHHS, NAHS, HOS) ($P < .0001$) (Table 4, Figure 4). There was an overall

TABLE 1
Demographics for Patients With Borderline Dysplasia Treated With Arthroscopy

Patients, No.	22
Age, average (range), y	20 (14-39)
Female, No.	18
Male, No.	4
Side, No.	Left, 11; right, 11
Tönnis angle, mean (range)	5.8° (0° - 17°)
Lateral CE angle, mean (range)	22.2° (18° - 25°)
Length of follow-up, mean \pm SD, mo	27.5 ± 5.5

durability to the procedure, with no decreases in scores over time (Figure 5). The VAS improved significantly—from 5.8 to 2.9 ($P < .0001$) (Figure 6). Overall patient satisfaction was 8.4 ± 1.4 (mean \pm SD). Seventeen patients had good/excellent results (77%). Four of the patients without good/excellent results had fair results (>70 points mHHS), and the fifth patient went on to revision with improved pain symptoms at 3 months after revision. Three hips in 2 patients had progression from Tönnis grade 0 to 1 at an average of 24 months postoperatively, with no patient having escape of the femoral head. There were no

TABLE 2
Surgical Findings of Patients With Borderline
Dysplasia Undergoing Arthroscopy^a

Diagnosis	No. of Patients
Labrum tear type—Seldes ²⁸	
1	11
2	6
Combined	5
Total with labrum tear	22
Cartilage damage—ALAD grade ⁶	
1	9
2	7
3	3
4	0
Total with cartilage damage	19
Ligamentum teres tear	
Partial	12
Complete	1
Total with ligamentum teres tear	13

^aAcetabular labrum articular disruption (ALAD) grades: 1, softening of adjacent cartilage (wave sign); 2, early peel-back of cartilage, carpet delamination; 3, large flap; 4, loss of cartilage.

TABLE 3
Procedures Performed for Patients With Borderline
Dysplasia Undergoing Arthroscopy

Procedures	No. of Patients
Labral repair	21
Labral selective debridement	1
Capsular plication	22
Iliopsoas release	15
Ligamentum teres debridement	13
Osteoplasty	9
Chondroplasty	9
Trochanteric bursectomy	1
Loose body removal	0
Microfracture	0

complaints of stiffness after the procedure and no cases of adhesions requiring adhesion takedown. Pre- and postoperative ROM values are shown in Figure 7. There was a significant but mild decrease in external rotation, from 59° to 48°. There were no perioperative complications. Two patients (9%) required revision surgery. One patient is a collegiate gymnast who had an excellent result up to 18 months postoperatively, when she developed pain after heavy gymnastic activity. Interestingly, this patient also had sustained an ipsilateral nondisplaced lateral tibial plateau fracture 7 months after surgery while performing gymnastics. Findings at the time of revision surgery performed 27 months after the first hip arthroscopy showed acetabular labrum articular disruption (ALAD) grade 3 cartilage damage, loose sutures, and noticeable synovitis. The patient underwent loose body removal, chondroplasty, synovectomy, and capsular plication. Another patient underwent revision 8 months after the initial surgery. At 6 months postoperatively, the patient had an episode of

TABLE 4
Preoperative and Postoperative Patient-Reported
Outcome Scores^a

Outcome Measure	Preoperative Score	Postoperative Score	P Value
mHHS	69.0 ± 12.1	86.2 ± 12.7	<.0001
HOS-ADLS	72.9 ± 12.6	89.6 ± 12.3	<.0001
HOS-SSS	49.0 ± 15.6	77 ± 21.9	<.0001
NAHS	68.6 ± 11.7	85.9 ± 14.2	<.0001
VAS	5.8 ± 2.4	2.9 ± 2.2	<.0001
Satisfaction		8.4 ± 1.4	

^aValues are shown as mean ± standard deviation. HOS-ADL, Hip Outcome Score—Activities of Daily Living; HOS-SSS, Hip Outcome Score—Sport-Specific Subscale; mHHS, modified Harris Hip Score; NAHS, Non-Arthritic Hip Score.

transient dislocation after sliding into a base and twisting the hip. After the injury, the patient had continued pain, popping, and instability. At the time of revision arthroscopy, there was noted a full-thickness ligamentum teres tear and rupture of the capsule that had been previously repaired. The capsule tear was in a location proximal to the previous repair. Other findings included a small Seldes type 2 labral tear and grade 2 ALAD cartilage. The patient underwent revision labral repair, ligamentum teres debridement, and revision capsular plication with improvement in pain and function, scoring 85 on the mHHS at 2-year follow-up.

DISCUSSION

The results demonstrate that good surgical outcomes can be achieved in patients with borderline dysplasia when treated with labral preservation and capsular plication. The clinical improvement shown in this cohort is similar to the findings of other studies reporting clinical outcomes in patients undergoing hip arthroscopy for treatment of femoroacetabular impingement.^{3,4,26} This remains a difficult problem to treat in high-demand patients.

Patients who are classified as having borderline dysplasia are far different than those with true dysplasia. The structure of the hip with dysplasia is not capable of withstanding the abnormal contact forces placed on the cartilage and labrum, leading to premature instability and osteoarthritis.²⁰ Capsulotomy in this setting can accelerate this process.¹⁹ Patients with borderline dysplasia, although having slightly abnormal architecture and thus increased contact forces, become symptomatic from the microinstability that occurs in this setting. The increased translational forces of the femoral head put the labrum at risk of injury as the capsule assumes an increased role in providing stability to the hip.² As the static stabilizers become damaged or stretched, the dynamic stabilizers around the hip become burdened and the surrounding musculature becomes symptomatic. In this setting, capsular plication is theorized to decrease this abnormal translational motion and protect the articular cartilage and labrum from further injury.^{1,10}

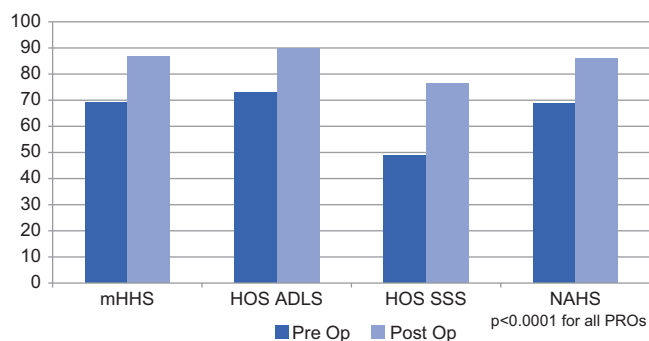


Figure 4. Preoperative and postoperative patient-reported outcome scores (PROs) for a cohort of patients with borderline dysplasia undergoing hip arthroscopy. HOS-ADL, Hip Outcome Score–Activities of Daily Living; HOS-SSS, Hip Outcome Score–Sport-Specific Subscale; mHHS, modified Harris Hip Score; NAHS, Non-Arthritic Hip Score.

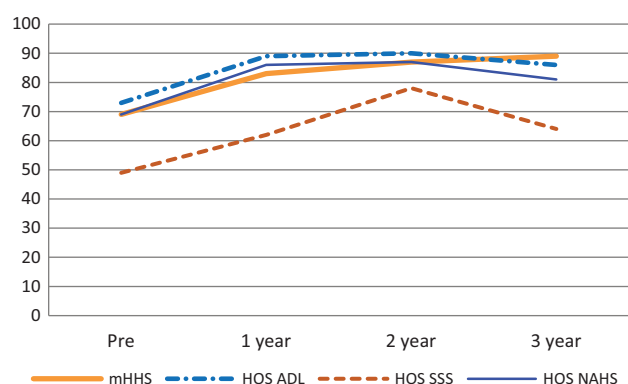


Figure 5. Patient-reported outcome scores preoperatively and at 1-year, 2-year, and 3-year follow-up. There was an overall durability to the procedure with significant increases from preoperative scores. HOS-ADL, Hip Outcome Score–Activities of Daily Living; HOS-SSS, Hip Outcome Score–Sport-Specific Subscale; mHHS, modified Harris Hip Score; NAHS, Non-Arthritic Hip Score.

Previous studies demonstrating the outcomes of treatment in patients with varying degrees of dysplasia have been inconclusive.^{5,25} As well, case reports have shown catastrophic outcomes after hip arthroscopy in the setting of dysplasia.^{19,27} A study by Parvizi et al²⁵ demonstrated poor outcomes in a cohort of patients classified with dysplasia (acetabular index <20°) who were treated with arthroscopy. The authors state that there was a decrease in super simple hip scores (SUSHI) to 74; however, preoperative and early postoperative values were not provided. From these results, the authors have abandoned hip arthroscopy in the setting of dysplasia. With studies such as this and the numerous case reports showing poor outcomes, there is not much doubt that hip arthroscopy in the setting of severe dysplasia is a relative contraindication and should be limited to treatment of intra-articular labral and cartilage damage at the time of PAO.

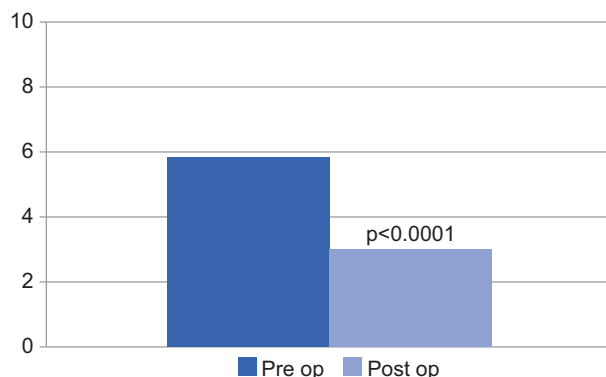


Figure 6. Visual analog scale demonstrating significant decrease in pain level postoperatively.

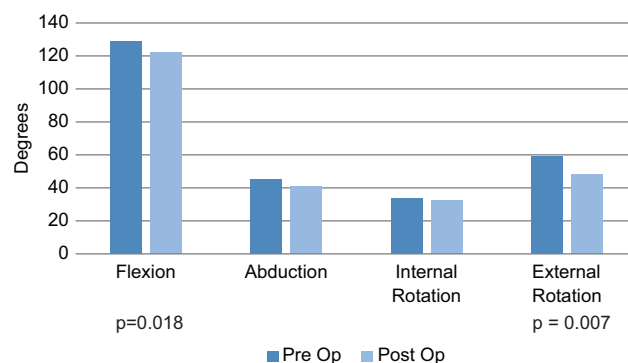


Figure 7. Preoperative and postoperative range of motion values. Postoperative range of motion was significantly decreased in flexion and external rotation.

In contrast to the results of hip arthroscopy in severe dysplasia, good results have been shown in milder forms of dysplasia. In an article by Byrd and Jones⁵ 48 patients with borderline dysplasia (20°-25°) and dysplasia (<20°) had a significant improvement in the mHHS score of 27 points. Thirty-eight patients showed at least a 10-point improvement, and 2 patients required conversion to total hip arthroplasty at 12 and 23 months. This cohort included patients older than 40 years, making comparisons to our cohort more challenging. Additionally, capsular plication was not performed in this cohort. These results, combined with ours, demonstrate that mild levels of dysplasia can be successfully treated with hip arthroscopy, particularly when aimed at treating the instability.

Two of our patients required revision (9%). This is consistent with revision rates in arthroscopic FAI studies.¹⁸ Both revisions occurred in very high-demand athletes with several episodes of high stress placed on the hip. This is a common scenario in this population of young, active patients anxious to return to sports and activities, and it highlights one of the difficulties in managing these patients.

One of the goals of this article is to show the safety as well as efficacy of the procedure. Radiographic follow-up demonstrated clinically insignificant progression of arthritis in 2 patients and no cases of femoral head escape, a devastating consequence in this at-risk population. Additionally, the significant yet mild decrease in external rotation and the improvement in all PROs demonstrate the effectiveness of the procedure.

One of the strengths of this study is its prospective collection of clinical data. Patient-reported outcome scores are an invaluable tool for measuring clinical outcomes. The use of multiple scores allows researchers to look for consistency in patient reporting and to overcome ceiling effects that can occur. As mentioned before, there is no evidence for the use of a single score in hip arthroscopy, so multiple scores can better delineate surgical outcomes.³⁰

One of the weaknesses of this study is the small size of the cohort. One reason for this could simply be the lack of patients suffering from this disorder. This is a small group of patients who suffer from hip pain and have mild dysplasia, defined by a CE angle of 20° to 25°. Despite the size of the cohort, there were consistent results within the cohort, and we would expect this consistency to continue in a larger cohort. Length of follow-up is a limitation in that it is unknown whether the results will persist over time or whether there will be recurrence of pain due to the underlying bony deformity. Another limitation is the lack of a control group; it is difficult to clearly state that capsular plication and labral repair and preservation are the reasons for successful outcomes in this cohort undergoing multiple procedures. Controlled studies are needed in this area. However, substantial biomechanical evidence has emerged indicating that the anterior capsule is important in stability of the hip.^{16,21} The proposed control group would have to consist of patients with a capsulotomy left open, which is in itself a potentially harmful intervention. As such, we do not believe it would be ethical to perform a controlled study in the borderline dysplastic population where the anterior capsule is released or incised. Since the Halsted principles of surgery include closure of soft tissues,⁷ generally any incision made in a surgery is closed unless there is a reason for a release of such soft tissues. Therefore, the burden of proof lies not on the concept that repair of a capsular incision is justified but rather on the concept that capsular incision does not need to be repaired. The objective of this study was to report initial clinical results and the safety of a procedure in a difficult cohort of patients, offering a soft tissue solution to a bony problem. Long-term follow-up of this cohort and larger cohorts will aid in determining the durability of this surgical approach in this patient population.

CONCLUSION

This study demonstrates that patients with borderline dysplasia can be successfully managed with hip arthroscopy when a consistent surgical approach is taken that includes labral preservation and capsular plication. This surgical approach should be considered in the management of

a patient who has sufficient acetabular coverage and does not require a PAO but has mild dysplasia that could be exacerbated with hip arthroscopy.

A Video Supplement for this article is available in the online version or at <http://ajsm.sagepub.com/supplemental>.

REFERENCES

1. Bedi A, Galano G, Walsh C, Kelly BT. Capsular management during hip arthroscopy: from femoroacetabular impingement to instability. *Arthroscopy*. 2011;27(12):1720-1731.
2. Bowman KF Jr, Fox J, Sekiya JK. A clinically relevant review of hip biomechanics. *Arthroscopy*. 2010;26(8):1118-1129.
3. Byrd JW, Jones KS. Arthroscopic management of femoroacetabular impingement in athletes. *Am J Sports Med*. 2011;39(suppl):7S-13S.
4. Byrd JW, Jones KS. Arthroscopic management of femoroacetabular impingement: minimum 2-year follow-up. *Arthroscopy*. 2011;27(10):1379-1388.
5. Byrd JW, Jones KS. Hip arthroscopy in the presence of dysplasia. *Arthroscopy*. 2003;19(10):1055-1060.
6. Callaghan JJ, Rosenberg AG, Rubash HE. *The Adult Hip*. 2nd ed. Philadelphia, PA: Lippincott Williams & Wilkins; 2007.
7. Cameron JL. William Stewart Halsted. Our surgical heritage. *Ann Surg*. 1997;225(5):445-458.
8. Christensen CP, Althausen PL, Mittleman MA, Lee JA, McCarthy JC. The nonarthritic hip score: reliable and validated. *Clin Orthop Relat Res*. 2003;406:75-83.
9. Domb B, Hanypsiak B, Botser I. Labral penetration rate in a consecutive series of 300 hip arthroscopies. *Am J Sports Med*. 2012;40(4):864-869.
10. Domb BG, Philippon MJ, Giordano BD. Arthroscopic capsulotomy, capsular repair, and capsular plication of the hip: relation to atraumatic instability. *Arthroscopy*. 2013;29(1):162-173.
11. Domb BG, Shindle MK, McArthur B, Voos JE, Magennis EM, Kelly BT. Iliopsoas impingement: a newly identified cause of labral pathology in the hip. *HSS J*. 2011;7(2):145-150.
12. Fry R, Domb B. Labral base refixation in the hip: rationale and technique for an anatomic approach to labral repair. *Arthroscopy*. 2010;26(9 suppl):S81-S89.
13. Kalore NV, Jiranek WA. Save the torn labrum in hips with borderline acetabular coverage. *Clin Orthop Relat Res*. 2012;470(12):3406-3413.
14. Kim KI, Cho YJ, Ramteke AA, Yoo MC. Peri-acetabular rotational osteotomy with concomitant hip arthroscopy for treatment of hip dysplasia. *J Bone Joint Surg Br*. 2011;93(6):732-737.
15. Larson CM, Giveans MR. Arthroscopic management of femoroacetabular impingement: early outcomes measures. *Arthroscopy*. 2008;24(5):540-546.
16. Martin HD, Savage A, Braly BA, Palmer IJ, Beall DP, Kelly B. The function of the hip capsular ligaments: a quantitative report. *Arthroscopy*. 2008;24(2):188-195.
17. Martin RL, Philippon MJ. Evidence of validity for the hip outcome score in hip arthroscopy. *Arthroscopy*. 2007;23(8):822-826.
18. Matheny T, Kim YJ, Zurakowski D, Matero C, Millis M. Intermediate to long-term results following the bernese periacetabular osteotomy and predictors of clinical outcome: surgical technique. *J Bone Joint Surg Am*. 2010;92(suppl 1 pt 2):115-129.
19. Mei-Dan O, McConkey MO, Brick M. Catastrophic failure of hip arthroscopy due to iatrogenic instability: can partial division of the ligamentum teres and iliofemoral ligament cause subluxation? *Arthroscopy*. 2012;28(3):440-445.
20. Murphy SB, Ganz R, Muller ME. The prognosis in untreated dysplasia of the hip: a study of radiographic factors that predict the outcome. *J Bone Joint Surg Am*. 1995;77(7):985-989.
21. Myers CA, Register BC, Lertwanich P, et al. Role of the acetabular labrum and the iliofemoral ligament in hip stability: an in vitro bipplane fluoroscopy study. *Am J Sports Med*. 2011;39(suppl):85S-91S.

22. Nho SJ, Magennis EM, Singh CK, Kelly BT. Outcomes after the arthroscopic treatment of femoroacetabular impingement in a mixed group of high-level athletes. *Am J Sports Med.* 2011;39(suppl):14S-19S.
23. Nishii T, Sugano N, Tanaka H, Nakanishi K, Ohzono K, Yoshikawa H. Articular cartilage abnormalities in dysplastic hips without joint space narrowing. *Clin Orthop Relat Res.* 2001;383:183-190.
24. Nunley RM, Prather H, Hunt D, Schoenecker PL, Clohisy JC. Clinical presentation of symptomatic acetabular dysplasia in skeletally mature patients. *J Bone Joint Surg Am.* 2011;93(suppl 2):17-21.
25. Parvizi J, Bican O, Bender B, et al. Arthroscopy for labral tears in patients with developmental dysplasia of the hip: a cautionary note. *J Arthroplasty.* 2009;24(6 suppl):110-113.
26. Philippon MJ, Briggs KK, Yen YM, Kuppersmith DA. Outcomes following hip arthroscopy for femoroacetabular impingement with associated chondrolabral dysfunction: minimum two-year follow-up. *J Bone Joint Surg Br.* 2009;91(1):16-23.
27. Ranawat AS, McClincy M, Sekiya JK. Anterior dislocation of the hip after arthroscopy in a patient with capsular laxity of the hip: a case report. *J Bone Joint Surg Am.* 2009;91(1):192-197.
28. Seldes RM, Tan V, Hunt J, Katz M, Winiarsky R, Fitzgerald RH Jr. Anatomy, histologic features, and vascularity of the adult acetabular labrum. *Clin Orthop Relat Res.* 2001;382:232-240.
29. Steppacher SD, Tannast M, Ganz R, Siebenrock KA. Mean 20-year followup of Bernese periacetabular osteotomy. *Clin Orthop Relat Res.* 2008;466(7):1633-1644.
30. Tijssen M, van Cingel R, van Melick N, de Visser E. Patient-Reported Outcome questionnaires for hip arthroscopy: a systematic review of the psychometric evidence. *BMC Musculoskelet Disord.* 2011;12:117.
31. Tönnis D, Heinecke A. Acetabular and femoral anteversion: relationship with osteoarthritis of the hip. *J Bone Joint Surg Am.* 1999;81(12):1747-1770.
32. Wiberg G. Studies on dysplastic acetabular and congenital subluxation of the hip joint with special reference to the complication of osteoarthritis. *Acta Chir Scand.* 1939;83(suppl 58).

For reprints and permission queries, please visit SAGE's Web site at <http://www.sagepub.com/journalsPermissions.nav>